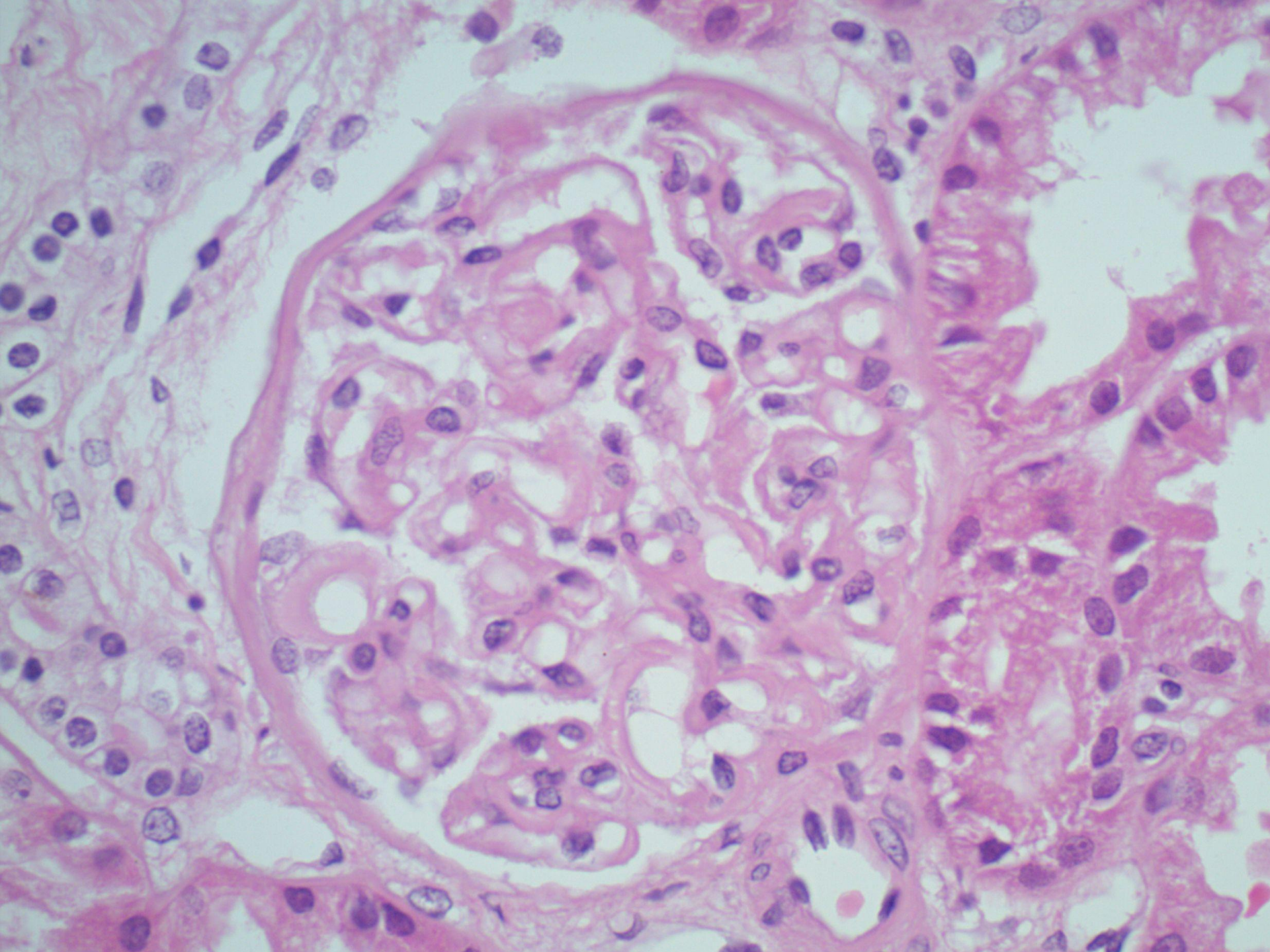
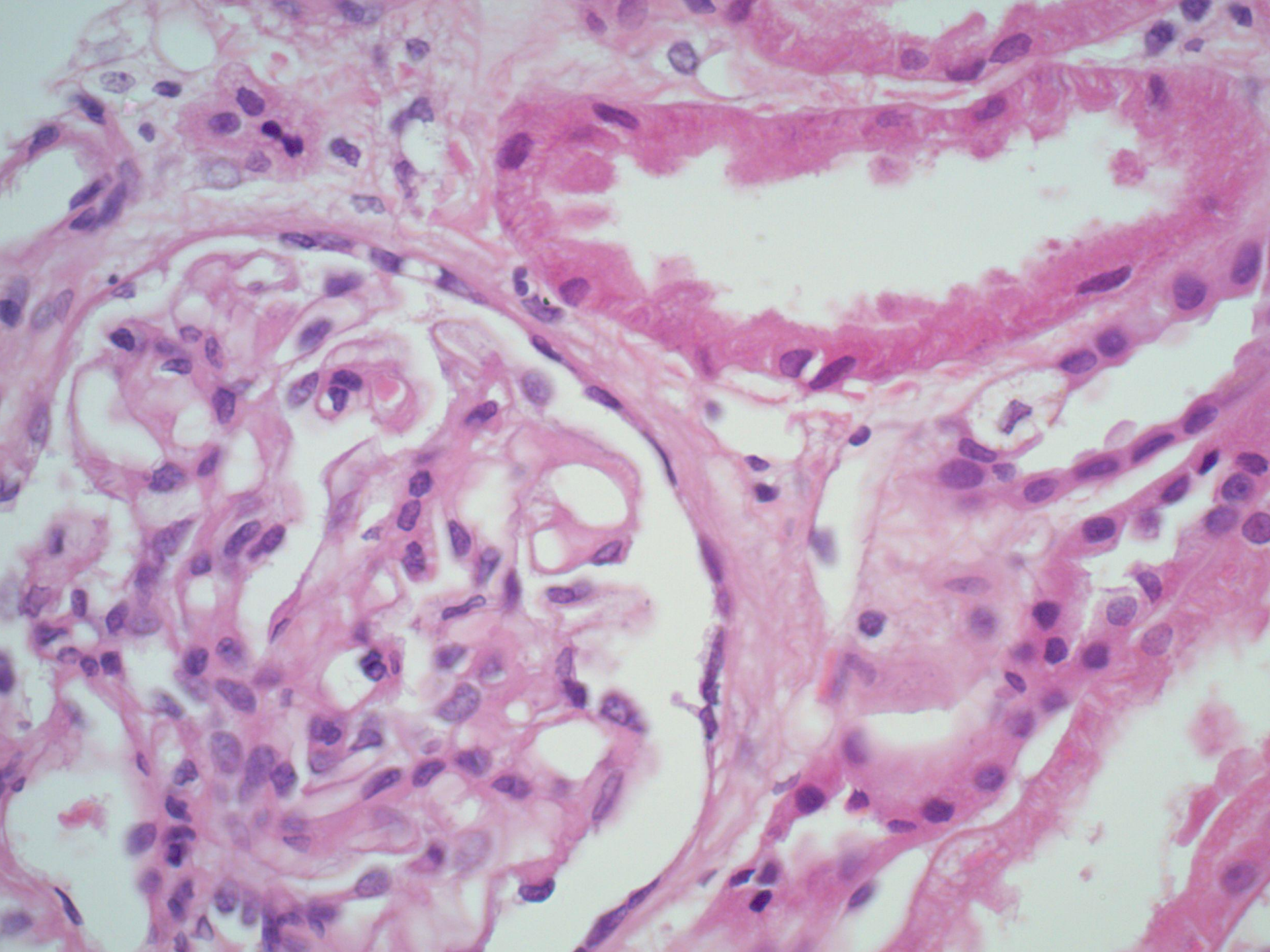
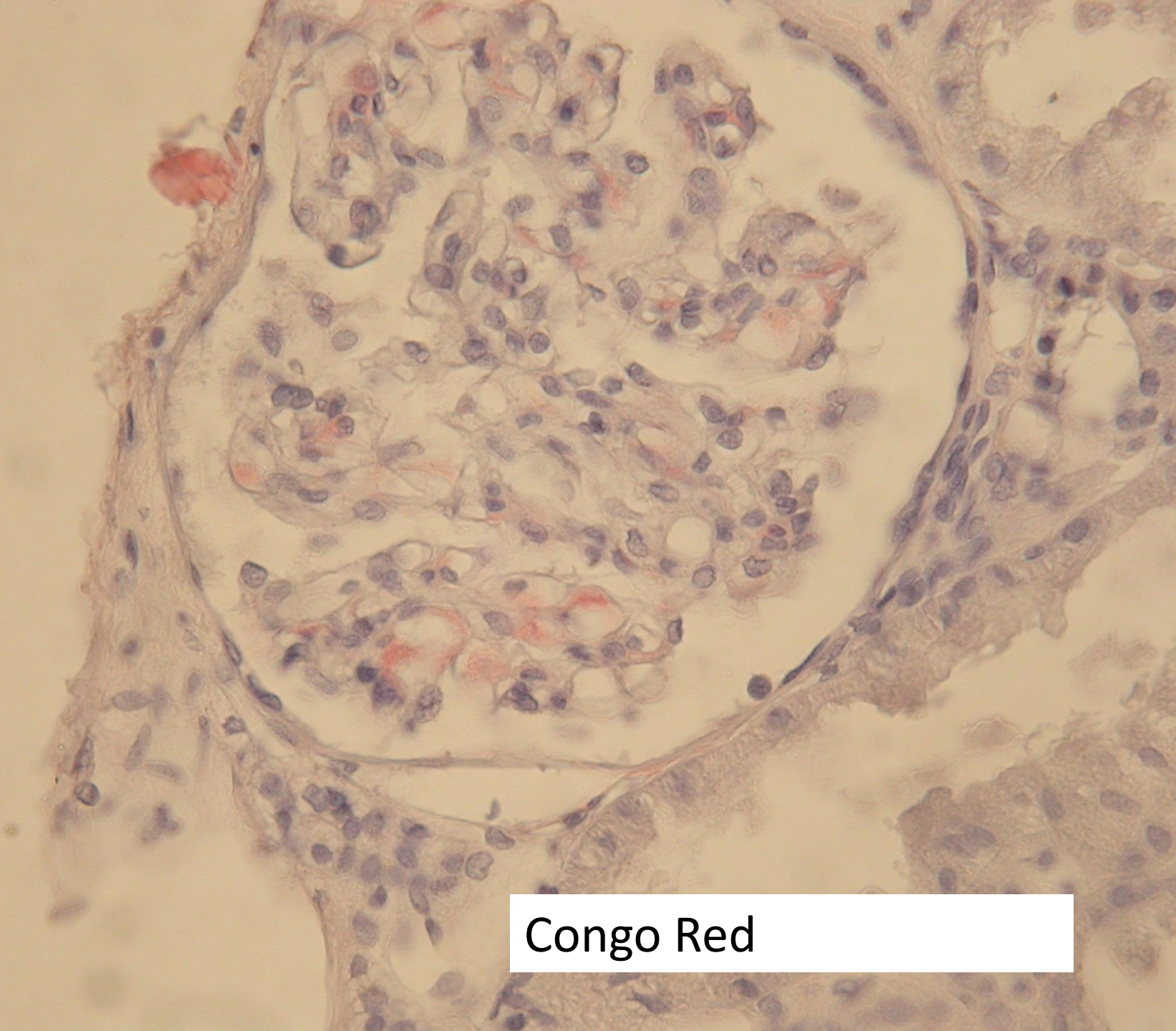


Case 4

- Male aged 63.
- 3 month history of nephrotic syndrome.
- No relevant past medical history.
- No new treatment.

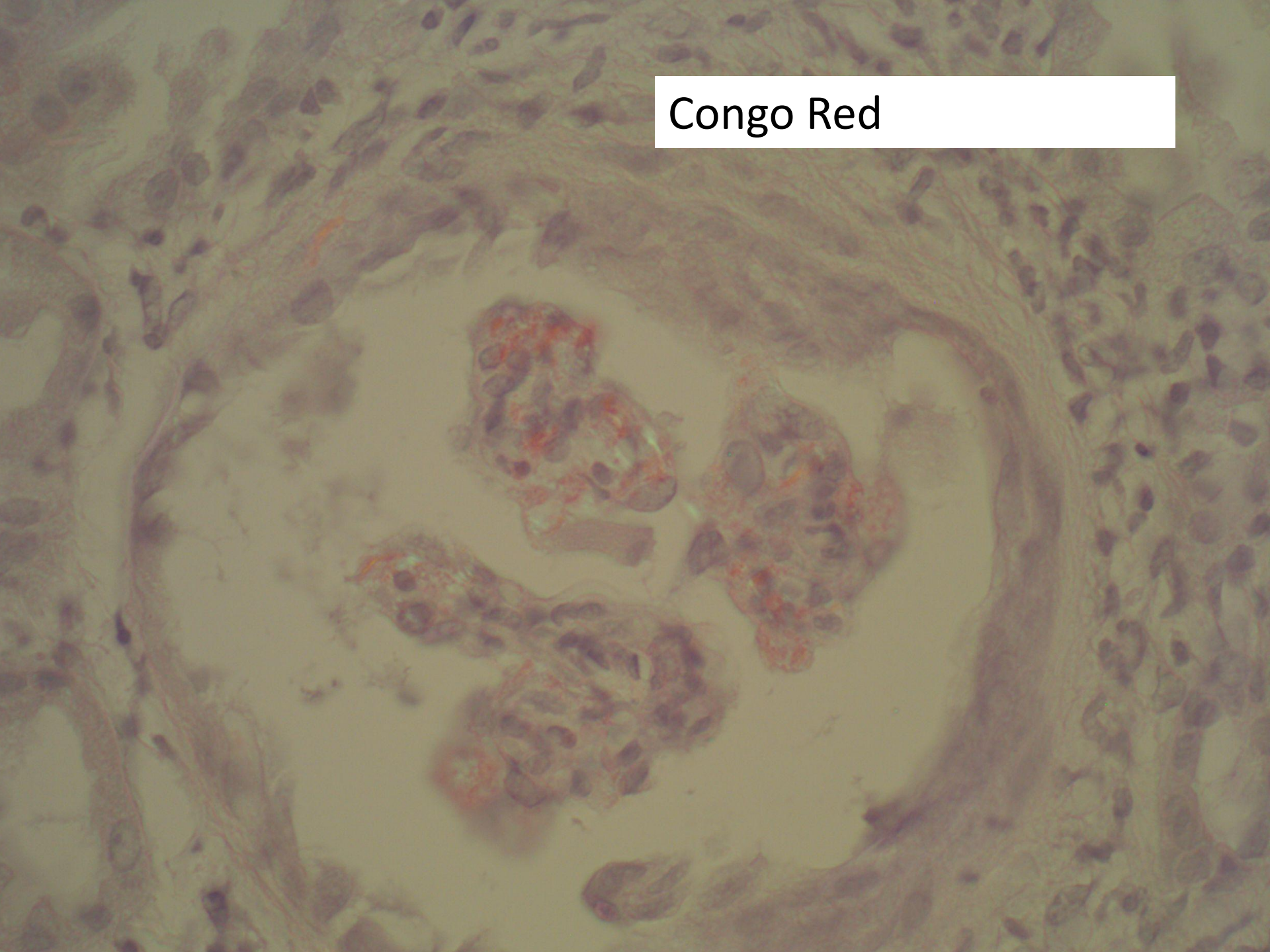


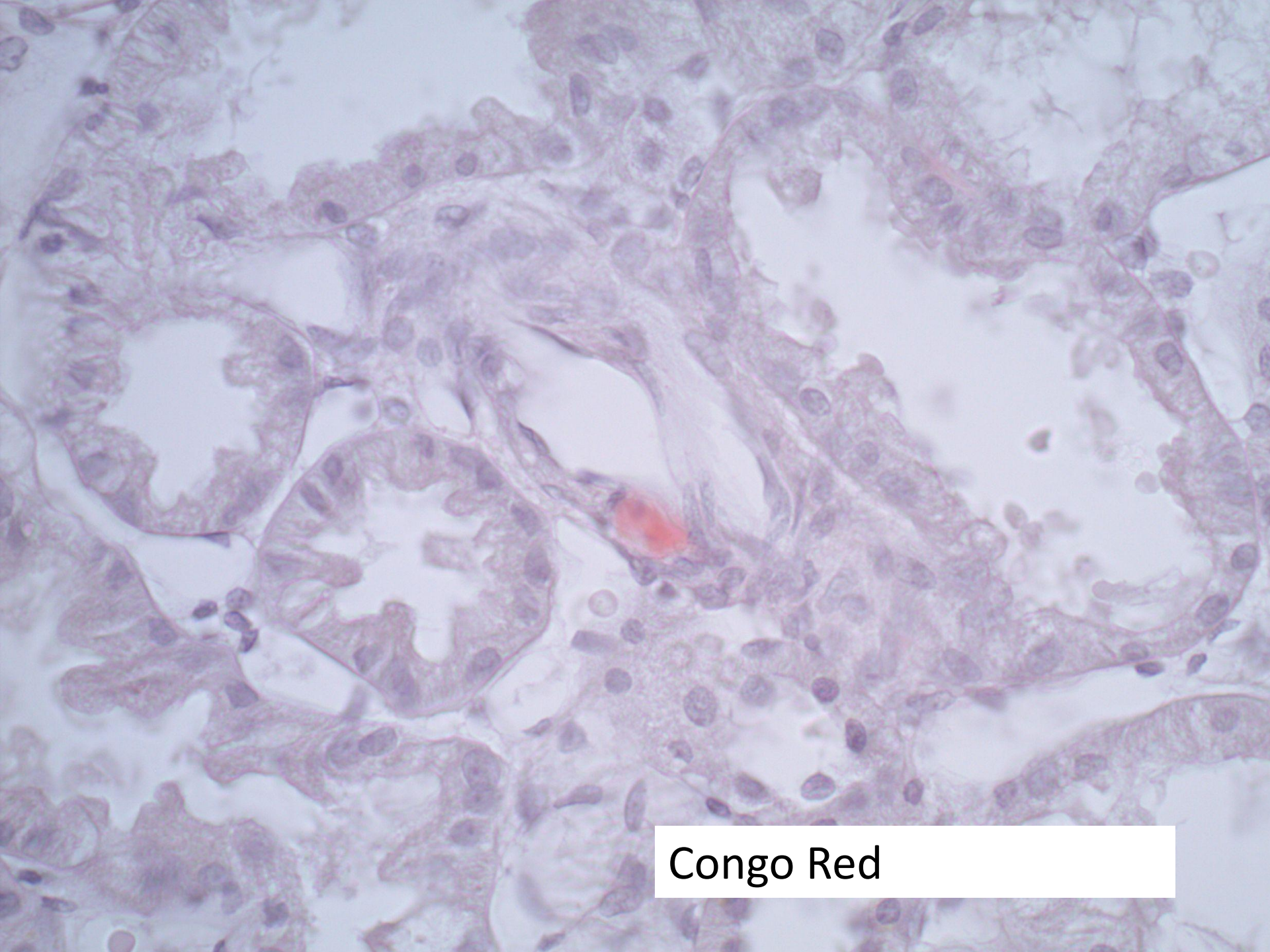




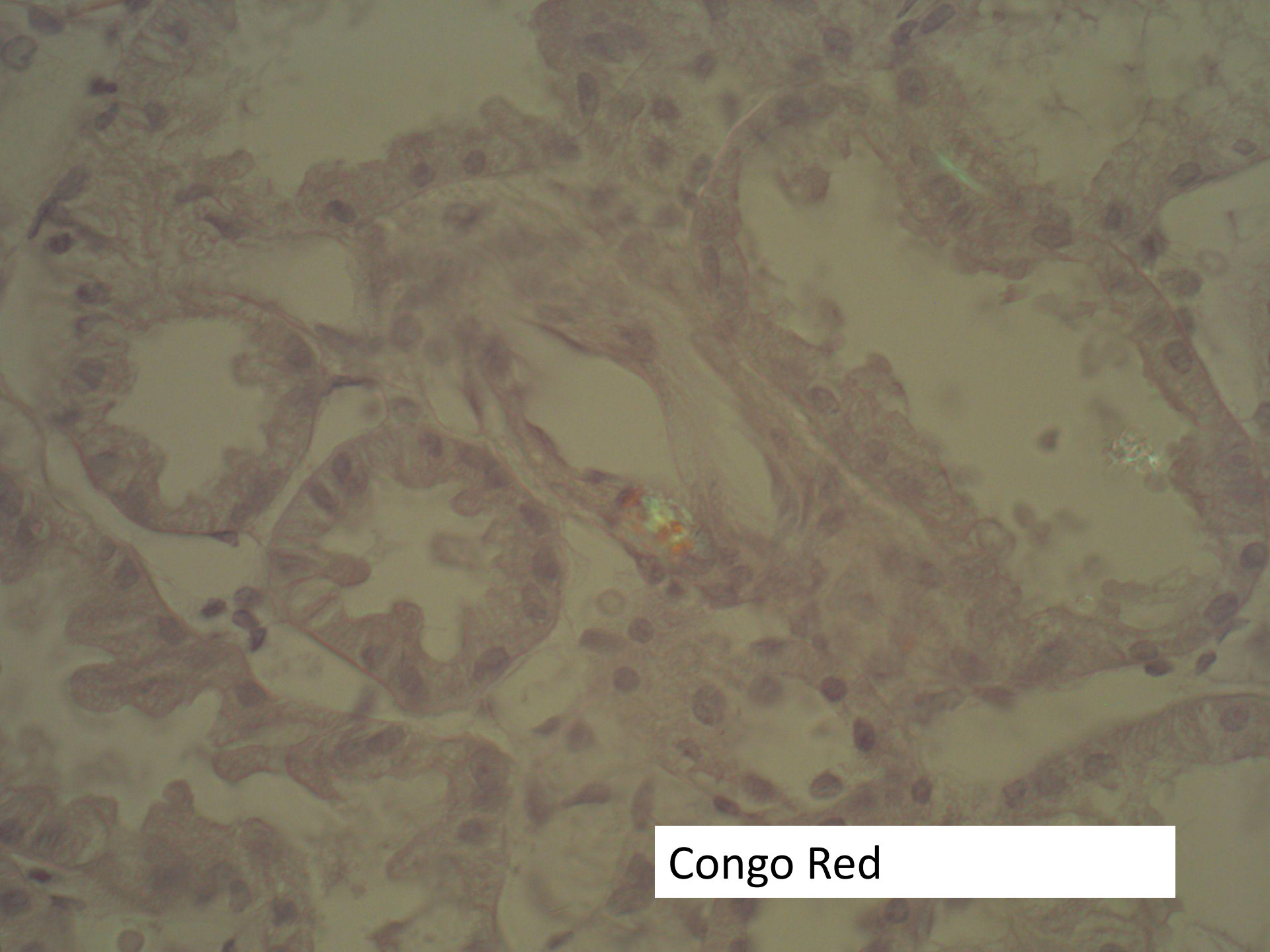
Congo Red

Congo Red

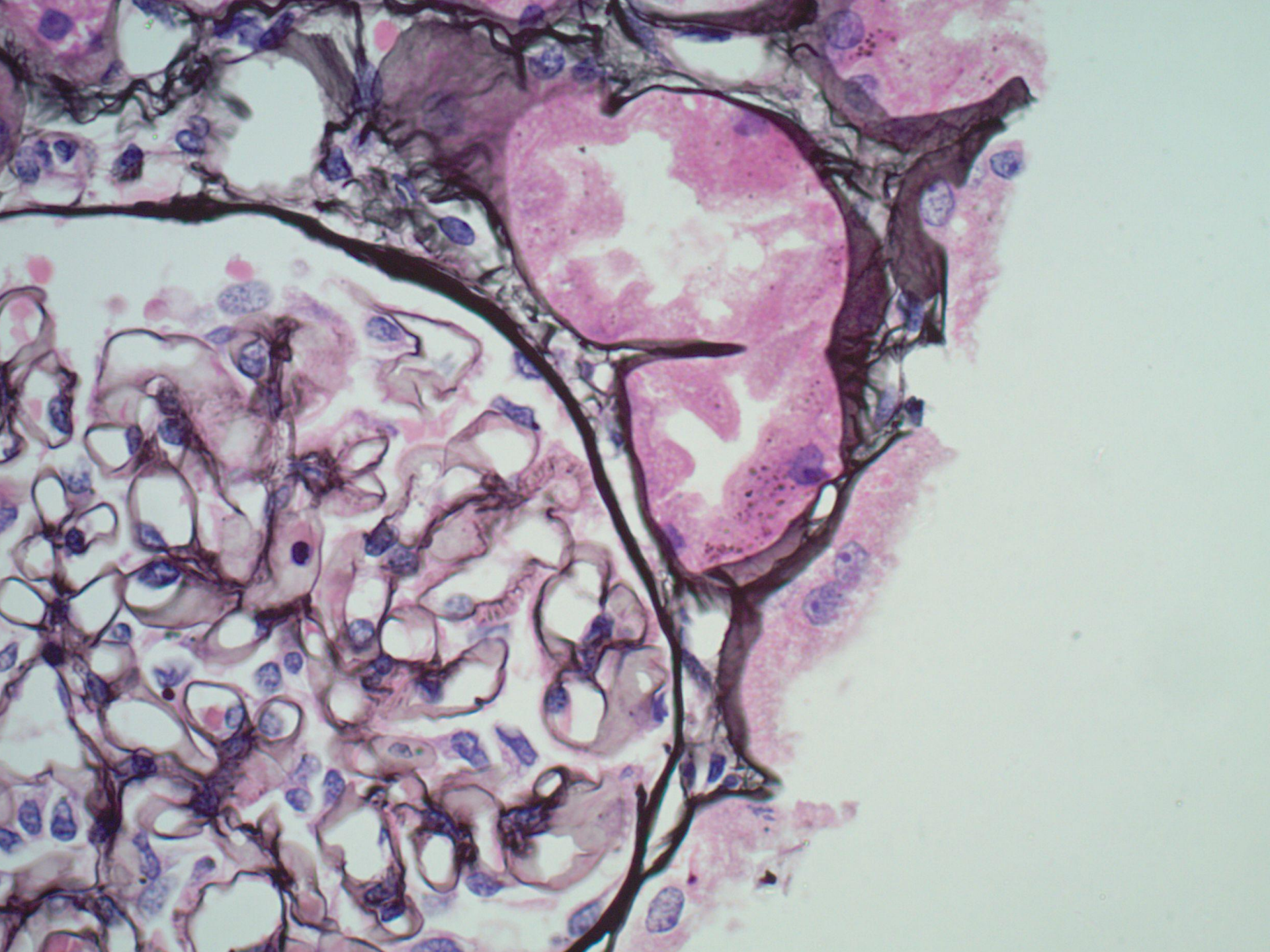


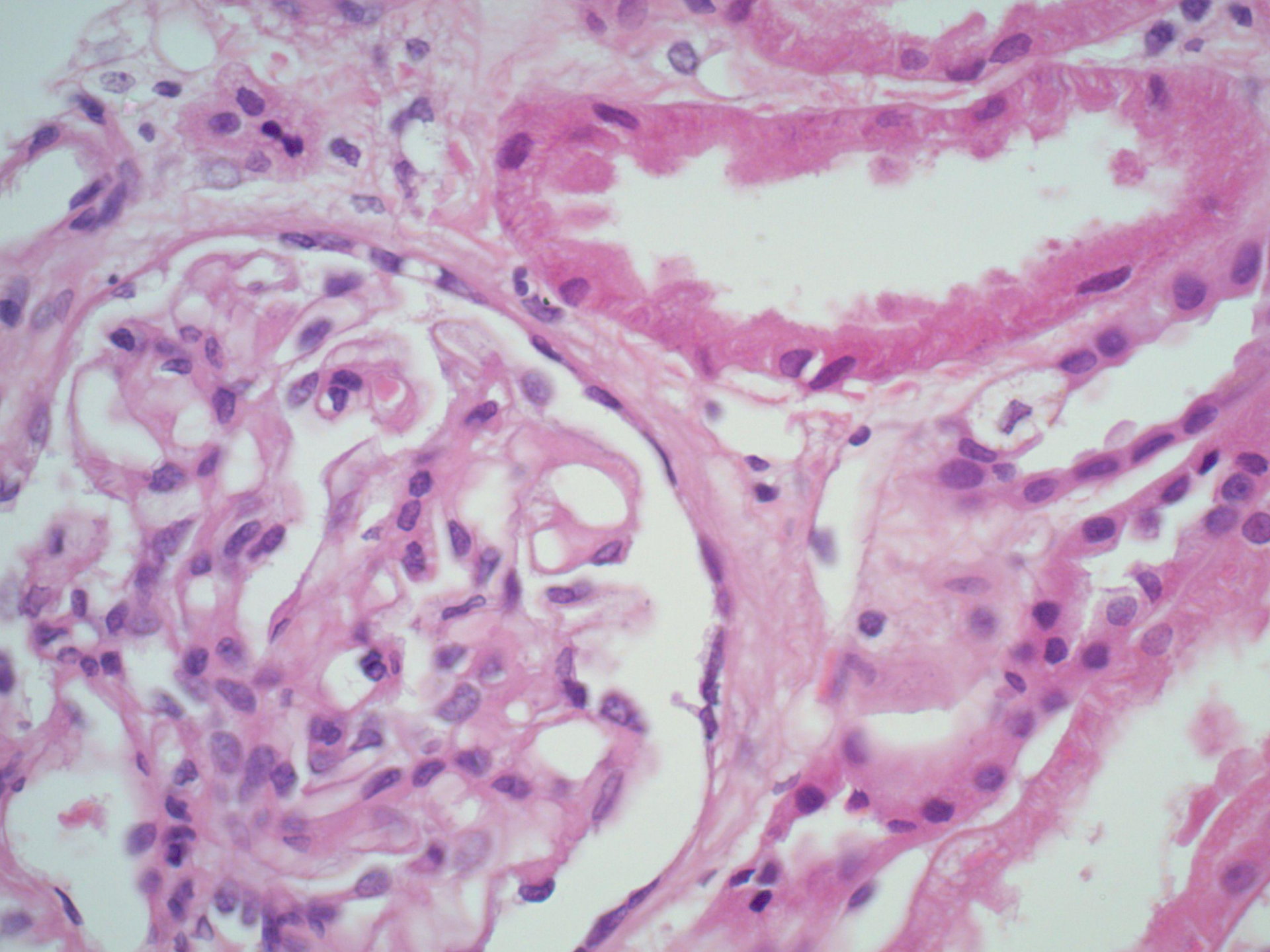


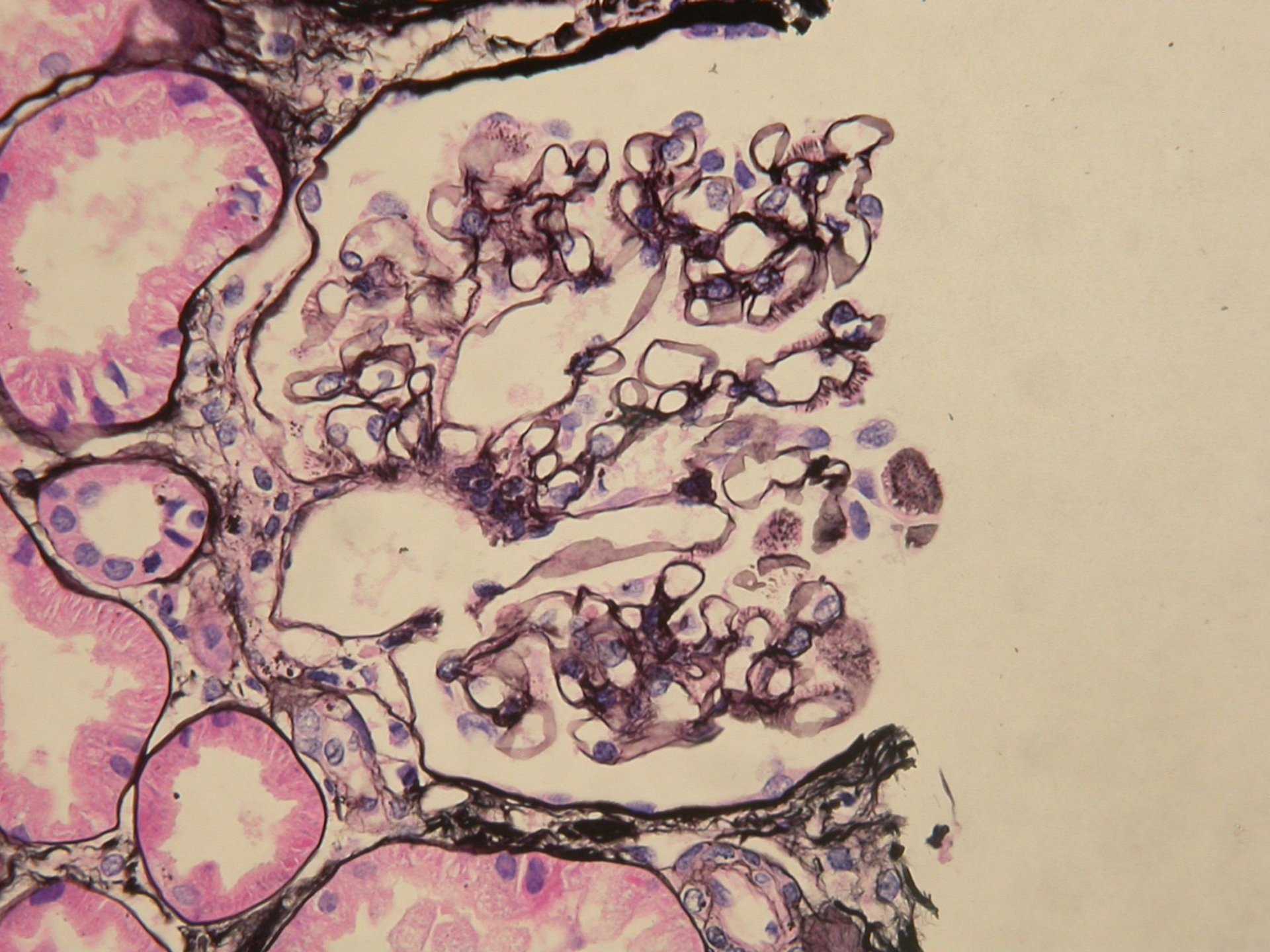
Congo Red



Congo Red

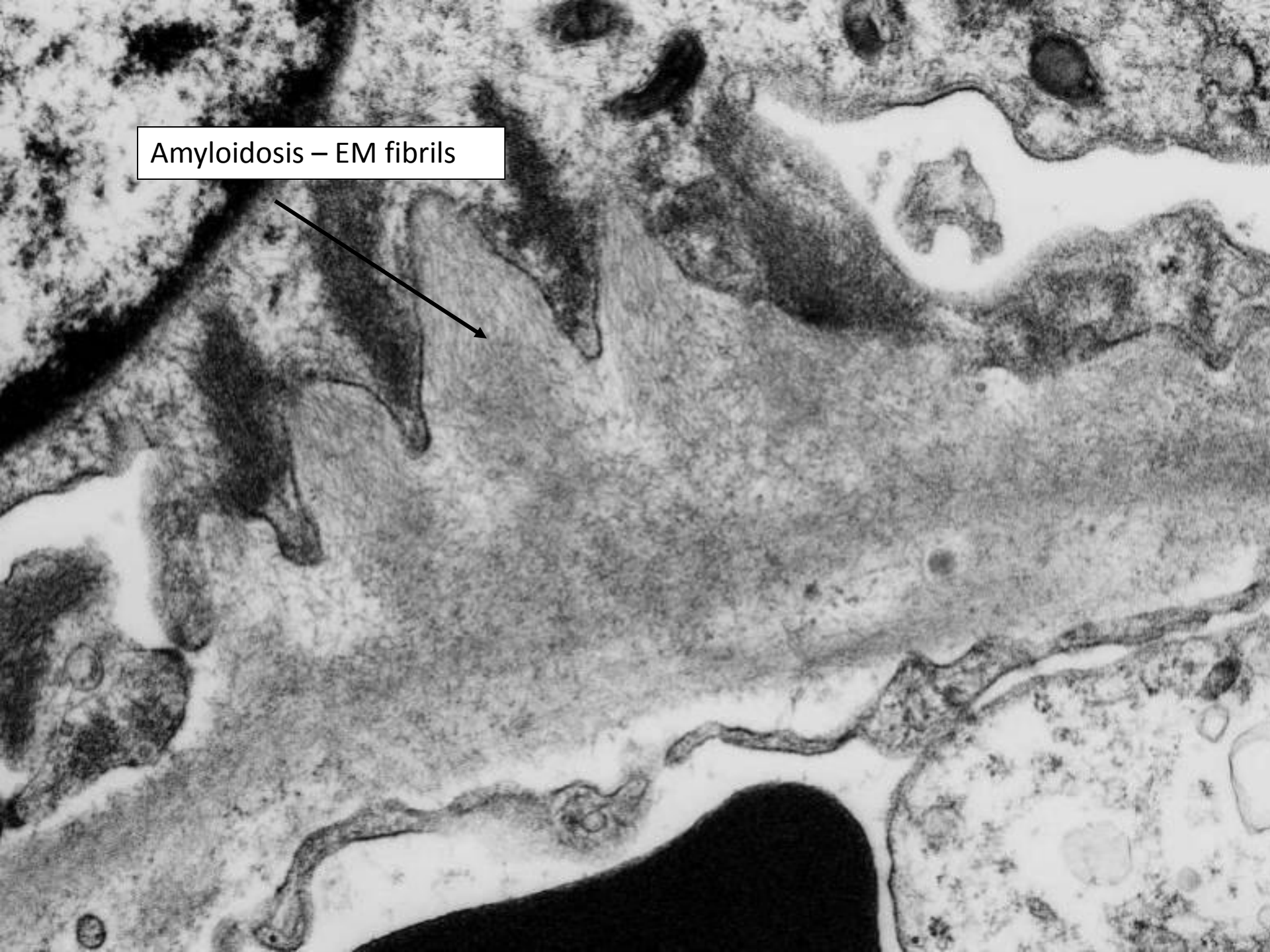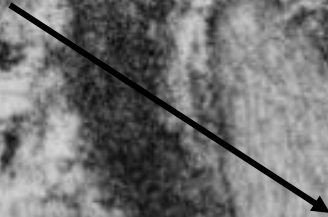







- What is the diagnosis?
- What other diagnoses are possible?
- What do you want to do to investigate further?

Amyloidosis – EM fibrils



Amyloidosis – EM fibrils

8-10nm, non-branching



Investigations

- Serum – paraprotein visible, but too small for quantification
- Low IgG
- Serum immunofixation – IgG lambda monoclonal
- Serum light chain ratio 0.49 (normal 0.260-1.650)
- Bone marrow – small aberrant B-cell population suggestive of low grade B-lymphoproliferative disease
- Echocardiogram – normal
- Skeletal survey negative
- Being treated with CTD